



Research Article

RECREATING FACIAL ESTHETICS USING DIFFERENT TYPES OF PLUMPER PROSTHESIS – CASE MANAGEMENT

¹Dr. Saba anjum, ²Dr. Prakash nidawani, ³Dr. Girish galagali, ⁴Dr. Harsha R.H, ⁵Dr. Srinivas reddy E and ⁶Dr. Satyanarayana naik

¹Post graduate student Department of Prosthodontics, Navodaya dental college, Raichur.

^{2,3,4,5,6} Professor Department of Prosthodontics, Navodaya dental college, Raichur.

ARTICLE INFO

Article History:

Received 6th July, 2020

Received in revised form 15th

August, 2020

Accepted 12th September, 2020

Published online 28th October, 2020

ABSTRACT

In today's appearance conscious world esthetics plays an important role. In complete denture treatment prosthodontist play a vital role in enhancing denture aesthetics not only in selecting and arranging teeth of appropriate form and size, shade, shape but also providing proper shade, shape and contour for denture base. In clinical situations like sunken cheeks or lips due to medially collapsed is quite challenging when these patients cannot be surgically managed due to systemic conditions they are best suited for non invasive management. This clinical report describes simple non invasive, economical, effective methods for enhancing denture esthetics in sunken cheek and lip patients managed to improve facial appearance with detachable plumper retained by press button and magnets.

Key words:

plumper prosthesis, it as non invasive management, Denture esthetics, Sunken cheeks, Rehabilitation

Copyright©2020 Dr. Saba anjum, Dr. Prakash nidawani, Dr. Girish galagali et al This is an open access article distributed under the Creative Commons Attribution License, which permits unrestricted use, distribution, and reproduction in any medium, provided the original work is properly

INTRODUCTION

Denture esthetic's according to glossary of prosthodontic terms-9 It is the effect produced by a dental prosthesis that affects the beauty and attractiveness of person.^[1] In today's generation patients are more conscious for appearance and demanding regarding external features of face. Facial esthetics plays a key role in every persons life. Lips and cheeks are important components of facial esthetics due to there extreme visibility.^[2] Facial aging is a process of soft tissue stretching due to submucous atrophy and inward displacement of soft tissue leads to appearance of sunken cheek or hollow cheek in patients.^[3] An edentulous patients due to aging suffers loss of alveolar process and teeth, loss of tonicity of musculature, loss of elasticity and impairment function.^[4,5,9]

When lips and cheek muscles become unsupported and weak then an adequate support by cheek lifting appliance required to improve appearance of patient by reducing sagging of cheeks due to enhance muscle tone. In medically compromised patients with loss of motor innervation to muscles controlling lips leads to paralysis where patient can not undergo surgery's in such situation it can be managed prosthetically with help of lip plumper.^[6,8]

***Corresponding author: Dr. Prakash nidawani**

Professor Department of Prosthodontics, Navodaya dental college, Raichur.

sunken cheek by extra features to denture to enhance facial esthetics.^[7]

CASE REPORT- 1 (LIP PLUMPER)

A 38 years old male patient reported to the department of prosthodontics crown and bridge including implantology, navodaya dental college and hospital, Raichur with chief complaint of multiple missing teeth in maxillary arch, intra oral examination revealed dentulous mandible arch deficit right maxillary ridge and bulbous left maxilla ridge with retained endodontically treated 23,24,25 (fig no.1) extra oral examination shows facial asymmetry with collapsed right side lip and excentuated naso labial fold as seen in (fig no.2) having retracted right corner of the mouth. Patient was diabetic having history of surgical extraction with 11,12,13,14 and alveolectomy for localized osteomyelitis (fig no.3) of the same. Patient was conscious about his facial asymmetric appearance. A treatment plan was derived keeping patients systemic and local conditions considering and his esthetic demand.

TREATMENT PROCEDURE

Decision to retain endodontically treated 23,24,25 was made considering superior support for the prosthesis these teeth were reduced to 1-1.5mm above the alveolar crest. Primary

impression of maxillary and mandible arches were made using alginate impression material using maxillary custom tray and final impression of upper arch was made with zinc oxide eugenol impression paste jaw relation recording were carried out. Wax up denture try in was carried out to check and correct occlusion and at the same appointment waxup lip/labial plumper (fig no.4) was attached to the upper trial denture then it was evaluated and adjusted to give balanced lip support. The transformation in the appearance with and without waxup lip plumper was observed and better appearance was readily accepted by the patient. Denture and plumper were separately processed with heat polymerising acrylic resin using compression moulding technique. After deflasking the cured final prosthesis (fig no.5) and plumper retrieved. Trimming, finishing and polishing procedures were performed corresponding holes of 2mm deep and 5mm wide diameter. Space was created using no.8 round bur upon right labial surface of processed denture and inner surface of lip plumper. Stainless steel press button were chosen (fig no.6) to attach lip plumper to right side of denture flange. Male and female components of press button were attached to lip plumper and denture flange correspondingly using self cure acrylic resin. Post denture insertion instructions (fig no.7) were given for the detachment and attachment of lip plumper according to the hygiene and esthetic need.

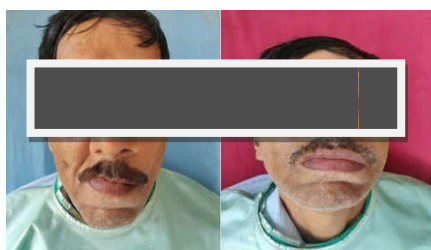

Fig 2

CASE REPORT- 2 (CHEEK PLUMPER)

A 54 years old male patient reported to the department of prosthodontics crown and bridge including implantology, navodaya dental college and hospital, Raichur with chief complaint of missing teeth and wanted to replace them, was also concerned about toothless looks and wanted to improve appearance from his prosthesis. Intra oral examination revealed upper and lower completely edentulous arches extra oral examination striking feature was collapsed cheek (fig no.8) considering the patients financial, constraints desires and need in mind treatment plan was made to fabricate upper and lower complete denture and provide a cheek plumper retained by magnet to give fullness to cheek and improve his appearance.

TREATMENT PROCEDURE

As of conventional complete denture procedure till waxup denture try in stage were completed at the try in stage occlusal, esthetics, phonetics were evaluated patient bilateral cheek support was noticed to be inadequate to improve shrunken cheek appearance modeling wax was incrementally added on right side second premolar to second molar and on the left side distal aspect of the canine to second molar by trial and error method (fig no.9) following functional muscle movements till satisfactory appearance was obtained after this stage the cheek

plumper wax patterns were separated. Both waxup denture and plumper pattern were separately acrylicised using compression moulding technique.(fig no.10) Considering the longer length of plumper on left side it was decided to use two magnets in comparison with one magnet on right side commercially available neodymium-iron-boron magnets (fig no.11) 2*5mm were fixed using self cure acrylic resin. Post denture insertion (fig no.12) instructions were given regarding its limitations, use, hygiene maintenance, attachment and detachment of cheek plumper patient was recalled for periodic followup.

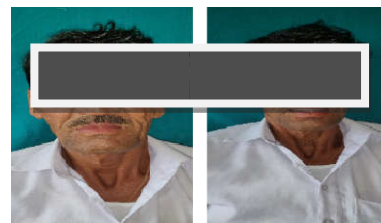

Fig 8

DISCUSSION

Loss of perioral support primarily affects lower part of the face in edentulous patients and restoration of appearance entirely depends on how much support denture provides intra orally to the lower half of the face. In several cases even after denture flange gives support wrinkling of skin and sagging of cheek and lip will continue to be noticed in such cases to provide additional support lifting appliance is required to enhance esthetics.^[8] A single unit plumper denture which support cheek and lip has major flaw in being bulky, heavy, difficulty in wearing denture in microstomia, limited mouth opening patient and its continuous wear may cause muscle fatigue. Detachable cheek and lip lifting appliance is more beneficial by permitting freedom to patient in choosing time to wear of plumper for esthetics in socialization, removal of plumper during mastication and during hygiene maintenance.^[9,2]

Various invasive and non invasive methods are carried out to recontour slumping cheek and lips by injecting botox in facial muscles and reconstructive plastic surgery and different type of prosthesis.^[10,11] In present cases management was carried out utilizing non invasive techniques.

For non invasive procedures various attachments like magnets and push buttons, customized attachments etc can be used to attach cheek plumper with denture in this article one case been using magnets a other with push buttons as these are managed effectively and easily attaches to denture.^[7]

In case 1 retained endodontically treated teeth on non affected side to enhance quality of support and aid in preserving remaining bone. Detachable lip plumper with press button being used for patient due to its advantage of snugfit to the denture for not only to correct cross lip asymmetry but also to prevent lip biting.^[6] In case 2 magnet detachable cheek plumper enable the patient to remove the plumper and use comfortably at will due to their small size, automatic seating and adequate holding capability.^[7,12]

However these type of detachable attachments require good manual dexterity for hygiene maintenance and regular periodic evaluation to assess efficacy of retentive forces when required to replace attachments.^[12,13] Both patients were given instructions about the procedure and made aware of limitations and recall visits after insertion of prosthesis.

Case Pictures: Case 1

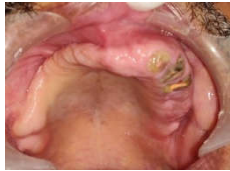

Fig 1 Intra oral

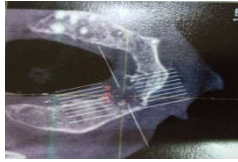


Fig 3 After surgical extraction of 11,12,13,14 & alvelectomy done

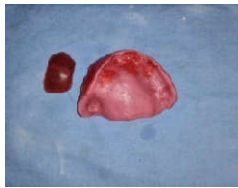

Fig 4 Waxup of labial plumper

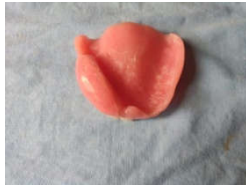

Fig 5 Acrylic denture

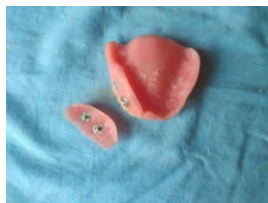

Fig 6 Denture with detachable labial plumper

Case 2

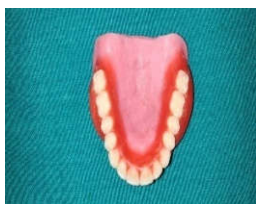

Fig 9 Modelling wax incrementally added

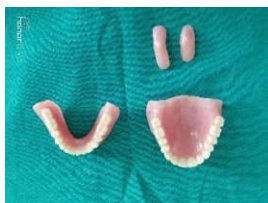

Fig 10 Acrylic denture

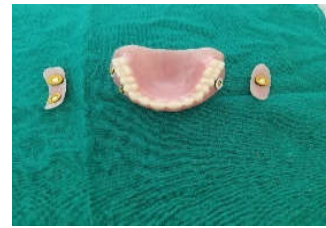

Fig 11 Cheek plumper with magnet

References

1. The journal of Prosthetic dentistry 2017;117(5):37.
2. Nandita N. Keni, Meena A. Aras, VidyaChitre Customised Attachments Retained Cheek Plumper Prosthesis: A Case Report. *J Indian Prosthodont Soc* (July-Sept 2012) 12(3):198-200
3. The role of facial skeletal augmentation and dental restoration in facial rejuvenation Jerry W. Bains, M.D. and James P. Elia. D.D.S, *Aesth. plastic surgery*. 1994 18: 243-246,
4. Muneet Kaur Marwahl, K. Harshakumar, R. Ravichandran, S. Lylajam Detachable Magnet Retained Cheek Plumpers To Enhance Complete Denture Esthetics - A Case Report. *ijhsr*. 2016 Vol.6; Issue: 7; July
5. Aggarwal P, Gupta M R, Pawah S, Singh P An Innovative Technique to Improve Complete Denture Aesthetics Using Cheek Plumper Appliance: A Case Report *International Journal of Oral Health and Medical Research* July-August 2016 | VOL 3 | ISSUE 2
6. Panthi S, Kamra M, Khosla, Sharma A, Kapoor S Modified Complete Denture Prosthesis to Support Lip and Improve Speech in Completely Edentulous Patients with Neurological Problem—A Case Report *DJAS* 5(III) 2017, 127-129,
7. Deogade .s.c Magnet Retained Cheek Plumper in Complete Denture Esthetics: A Case Report *Journal of Dentistry, Tehran University of Medical Sciences* January 2014; Vol. 11, No. 1
8. Folkins JA, MacLeod WD. An intraoral appliance for facial paresis. *Can Med Assoc J* 1953;69(6):632-633
9. Saini, S H, Jain S, Kumar S, Aggarwal R, Choudhary S, Joshi S Rehabilitating smiles using detachable cheek plumper prosthesis- A case report *ejpmr*, 2017;4(12), 457-461.
10. Jess Dhaliwal, Oren Friedman. Injectables and facial in male patients. *Facial Plast Surg Clin N Am* 2008; 16:345-355
11. John B. Lazzari. Intraoral splint for support of lip in Bell's Palsy. *J prosthet dent* 1955; 5:579-81
12. Young HA. Denture esthetics. *J Prosthet Dent*. 1956;6(6):748-55.
13. Kamakshi V, Anehosur GV, Nadiger RK. Magnet retained cheek plumper to enhance denture esthetics: case reports. *J Indian Prosthodont Soc*, 2013; 13: 378-81.
