



## PERFORATED PERITONITIS DUE TO SPONTANEOUS RUPTURE OF LARGE GIST ARISING FROM SMALL BOWEL- A RARE CASE REPORT

Dr Madhu Sudan Modi , Dr. Hamza Wani, Dr. Uppalapati Srinivasulu,  
Dr .Bikas Agarwal and Dr. Md. Ibrarullah

Department of surgical Gastroenterology, Apollo Hospitals, Bhubaneswar

### ARTICLE INFO

**Article History:**

Received 06<sup>th</sup> September, 2019

Received in revised form 14<sup>th</sup>

September, 2019

Accepted 23<sup>rd</sup> November, 2019

Published online 28<sup>th</sup> December, 2019

**Key words:**

GIST ( Gastro Intestinal Stromal Tumour),  
Perforation, small intestine

### ABSTRACT

**Introduction:** Gastro intestinal stromal tumors (GISTs) are the most common mesenchymal tumors of the gastro intestinal tract. Overt peritonitis caused by GIST rupture is very uncommon. Three types of GIST rupture have been described: closed perforation due to abscess (abscess type), hemoperitoneum leading to rupture of the hematoma capsule in the tumor (hemoperitoneum type), and perforation of the digestive tract via a fistula leading to central necrosis of the tumor (bowel perforation type). This report describes a patient with spontaneous tumor rupture and diffuse peritonitis, a variant of the bowel perforation type of GIST rupture.

**Presentation of Case:** A 47-year-old female presented with symptoms of abdominal pain, distension & vomiting since 4 days .Computed tomography (CECT) scan revealed- Large enhancing necrotic mesenteric mass in pelvic region measuring 8x7 cm attached to the wall of mid small bowel with focal perforation of the lesion, likely GIST – with perforation. Emergency laparotomy revealed a tumor in the Proximal ileum which was ruptured with a hole measuring 1cm in diameter. The tumor and part of the ileum were resected along with adherent part of urinary bladder wall. Histopathological examination shows- Spindle Cell Neoplasm Favouring Gastro Intestinal Stromal ( GIST )Tumour.

**Conclusions:** This report describes a patient with acute diffuse peritonitis due to spontaneous rupture of a primary GIST of the proximal ileum.

Copyright©2019 Dr Madhu Sudan Modi , Dr. Hamza Wani and Dr .Uppalapati. This is an open access article distributed under the Creative Commons Attribution License, which permits unrestricted use, distribution, and reproduction in any medium, provided the original work is properly cited.

### INTRODUCTION

Gastrointestinal stromal tumors (GISTs) are the most common mesenchymal tumor of the gastrointestinal tract [1]. The clinical symptoms of GIST complications include vague abdominal pain, hematemesis, and intestinal obstruction. However, overt peritonitis caused by GIST rupture is very uncommon [2]. Three types of GIST rupture have been described to date: closed perforation due to abscess (abscess type), hemoperitoneum leading to rupture of the hematoma capsule in the tumor (hemoperitoneum type), and perforation of the digestive tract via a fistula leading to central necrosis of the tumor (bowel perforation type). This report describes a patient with spontaneous tumor rupture and diffuse peritonitis, a variant of the bowel perforation type of GIST rupture.[3]

**Presentation of case**

A 47-year-female presented with symptoms of abdominal pain, distension & vomiting since 4 days. Her body temperature was 100F; blood pressure, 100/60mmHg;

radial pulse rate, 98beats/minute. Abdominal examination revealed distension & diffuse tenderness. Blood tests showed Hb-8.5g/dl, white blood cell count of 17600/mm<sup>3</sup>,

Computed tomography (CECT) scan revealed- Large enhancing necrotic mesenteric mass in pelvic region measuring 8x7 cm attached to the wall of mid small bowel with focal perforation of the lesion, likely GIST – with perforation (Fig.1a,1b). Emergency laparotomy revealed fecal peritonitis, large vascular mass arising from proximal ileum on antimesenteric border & adherent to urinary bladder with perforation. Mass resected along with cuff of urinary bladder wall & involved small bowel (Fig 2a,2b). Small bowel closed primarily & bladder repair done. Peritoneal wash done. Abdominal layers closed . specimen sent for HPE.

\*Corresponding author: Dr Madhu Sudan Modi

Department of surgical Gastroenterology, Apollo Hospitals,  
Bhubaneswar

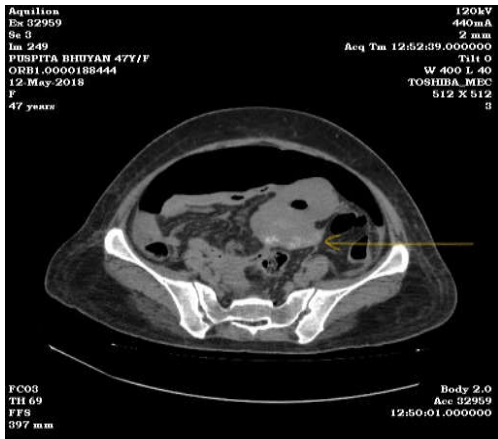

Fig.1a CT- GIST perforation

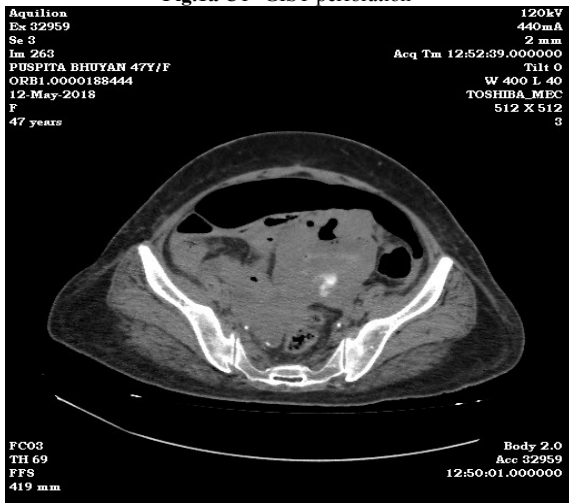


Fig. 1b CT-GIST perforation

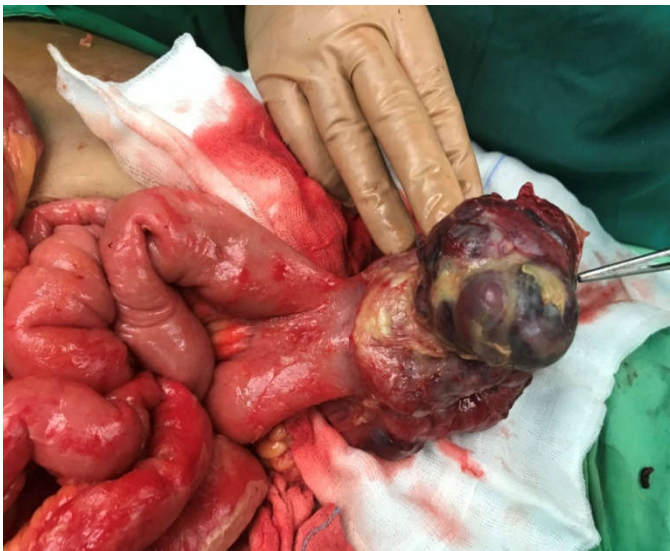

Fig.2a Small intestine GIST

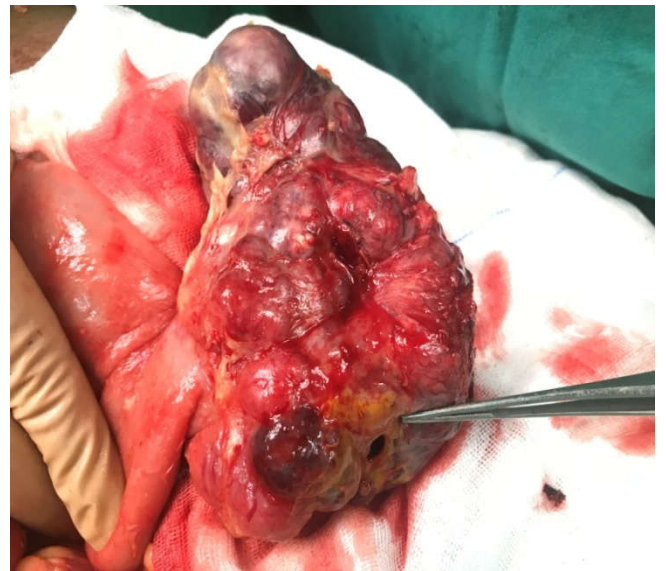

Fig.2b Small intestine GIST

HPE Report shows- Spindle Cell Neoplasm Favouing Gastro Intestinal Stromal (GIST )Tumour (Fig 3).post operative period uneventfull & Patient discharged on 11<sup>th</sup> post op day.

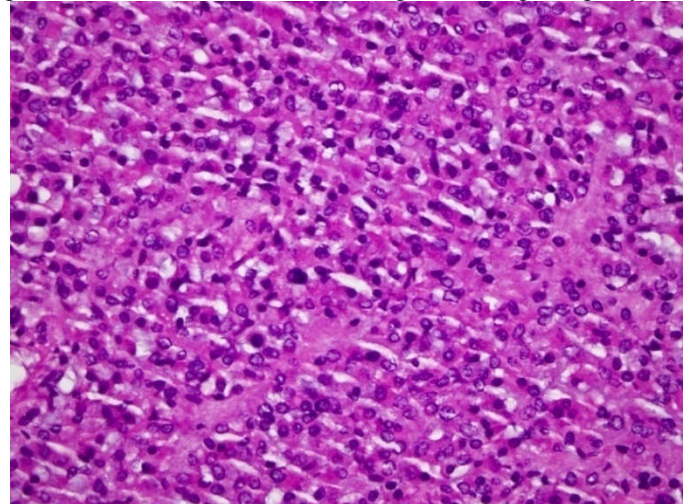


Fig 3 Histopathology of specimen - showing spindle cells (GIST).

## DISCUSSION

GISTs are visceral tumors arising from any site within the gastro intestinal tract. Approximately 60–70% of these tumors occur in the stomach, 25–35% in the small intestine, and 10% in the jejunum, whereas the esophagus, colon, rectum, and appendix are rarely affected [4]. GISTs are usually associated with abdominal pain, palpable mass, and/or GI bleeding, accompanied by fever, anorexia, weight loss, and/or anaemia [5]. Approximately 10% of GISTs are located in the jejunum [6]. The most commonly reported clinical symptoms are bleeding and obstruction [7]. However, GISTs originating from the small bowel rarely cause perforation or cause acute diffuse peritonitis. Common symptoms of small intestinal GISTs include abdominal pain and a palpable mass, with early satiety and abdominal fullness also occurring frequently [8]. Fever, anorexia and weight loss are rarely observed [9].

## CONCLUSION

This report describes a patient with spontaneous rupture of a primary GIST of ileum presenting as acute abdomen and peritonitis which is rarely seen.

## References

1. M. Miettinen, H. Makhlof, L.H. Sobin, J. Lasota, Gastrointestinal stromal tumors of the jejunum and ileum: a clinico-pathologic, immune histochemical, and molecular genetic study of 906 cases before imatinib with long-term follow-up, *Am. J. Surg. Pathol.* 30 (4) (2006) 477–489.
2. C.Y. Wang, F. Du, S.M. Huang, Y.C. Tsai, Non traumatic hemoperitoneum due to spontaneous gastrointestinal stromal tumor rupture: a case report, *Chin. J. Radiol.* 34 (2009) 293–297.
3. R.A. Agha, A.J. Fowler, A. Saetta, I. Barai, S. Rajmohan, D.P. Orgill, the SCARE Group, The SCARE statement: consensus-based surgical case report guidelines, *Int. J. Surg.* 34 (2016) 180–186.
4. E.M. Connolly, E. Gaffney, J.V. Reynolds, Gastrointestinal stromal tumours, *Br. J. Surg.* 90 (10) (2003) 1178–1186.
5. A. Nowain, H. Bhakta, S. Pais, G. Kanel, S. Verma, Gastrointestinal stromal tumors: clinical profile, pathogenesis, treatment strategies and prognosis, *J. Gastroenterol. Hepatol.* 20 (6) (2005) 818–824.
6. S. Velasco, S. Milin, C. Maurel, J.P. Richer, C. Sylvain, J. Hannequin, *et al.*, Scanographic features of gastrointestinal stromal tumors, *Gastroenterol. Clin. Biol.* 32 (12) (2008) 1001–1013.
7. C.D. Fletcher, J.J. Berman, C. Corless, F. Gorstein, J. Lasota, B.J. Longley, *et al.*, Diagnosis of gastrointestinal stromal tumors: a consensus approach, *Int. J. Surg. Pathol.* 10 (2) (2002) 81–89.
8. N. Memmi, G. Cipe, H. Bektasoglu, T. Toydemir, H. Kadioglu, S. Bozkurt, *et al.*, Perforated gastrointestinal stromal tumor in the jejunum: a rare cause of acute abdomen, *Oncol. Lett.* 4 (6) (2012) 1244–1246.
9. T. Tran, J.A. Davila, H.B. El-Serag, The epidemiology of malignant gastro intestinal stromal tumors: an analysis of 1,458 cases from 1992 to 2000, *Am. J. Gastroenterol.* 100 (1) (2005) 162–168.

### How to cite this article:

Dr Madhu Sudan Modi *et al* (2019) 'Perforated Peritonitis Due to Spontaneous Rupture of Large Gist Arising from Small Bowel– A Rare Case Report', *International Journal of Current Advanced Research*, 08(12), pp. 20796-20798. DOI: <http://dx.doi.org/10.24327/ijcar.2019.20798.4071>

\*\*\*\*\*