

**ADULT POSTERIOR URETHRAL VALVE: A CASE SERIES**

**Aysha Shaheen, Senthilvel Arumugam, R. Govindarajan and D.Karthikeyan**

Department of Urology, Government Kilpauk Medical College, Chennai

**ARTICLE INFO**

**Article History:**

Received 10<sup>th</sup> September, 2019

Received in revised form 2<sup>nd</sup>

October, 2019

Accepted 26<sup>th</sup> November, 2019

Published online 28<sup>th</sup> December, 2019

**Key words:**

adult posterior urethral valve

**ABSTRACT**

Posterior urethral valve (PUV) with an incidence of 1/8.000 to 1/25.000 live births is the most common cause of lower urinary tract obstruction in male neonates [1], [2]. This pathology constitutes a clinical spectrum ranging from severe forms, with important repercussions on the upper urinary tract and renal function (RF), to milder forms. In our cases 4 males were diagnosed as posterior urethral, average age of patients were 28 years, 2 patients were referred to us from nephrology department as CKD stage 5 for transplant workup. other two patients came with obstructive lower urinary obstruction, All Patient underwent ablation of posterior urethral valve using Collin's knife .14 fr silastic catheter placed for all cases, postoperative uroflow done for all cases ,shows improvement in uroflow parameter.

*Copyright©2019 Aysha Shaheen, Senthilvel Arumugam, R. Govindarajan and D.Karthikeyan. This is an open access article distributed under the Creative Commons Attribution License, which permits unrestricted use, distribution, and reproduction in any medium, provided the original work is properly cited.*

**INTRODUCTION**

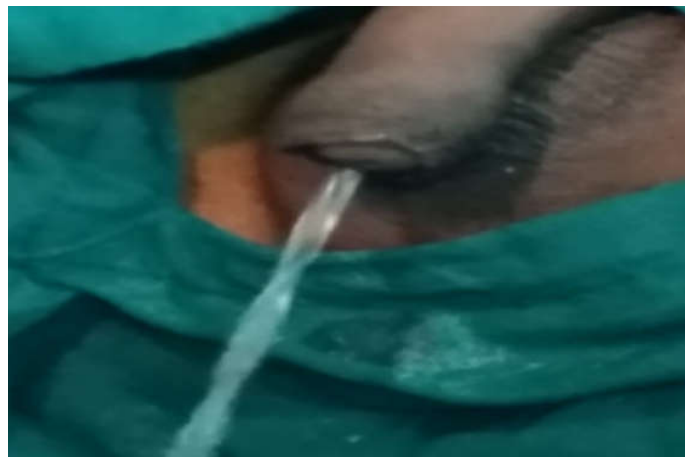
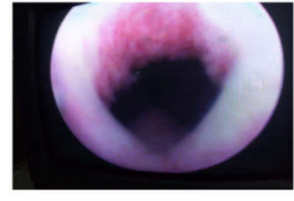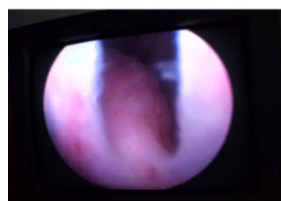
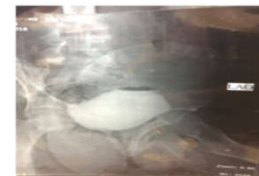
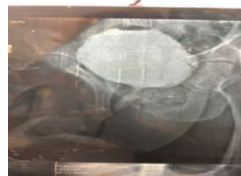Posterior urethral valve (PUV) with an incidence of 1/8.000 to 1/25.000 live births is the most common cause of lower urinary tract obstruction in male neonates<sup>[1], [2]</sup>. This pathology constitutes a clinical spectrum ranging from severe forms, with important repercussions on the upper urinary tract and renal function (RF), to milder forms<sup>[3], [4], [5]</sup>. When obstruction can be overcome by detrusor contraction it may remain silent until later life<sup>[1], [2]</sup>. The majority of cases are diagnosed in infancy and early childhood especially during evaluation of male newborn for prenatal hydronephrosis and rarely in adolescence or adulthood. The diagnosis of PUV is usually made early, and PUV cases have rarely been detected in adults<sup>[6], [7], [8], [9]</sup>.

**Presentation**

4 males were diagnosed as posterior urethral, average age of patients were 28 years, 2 patients were referred to us from nephrology department as CKD stage 5 for transplant workup. other two patients came with obstructive lower urinary obstruction, Uroflowmetry and screening ultrasound done for all cases, uroflow shows stricture pattern, antegrade and retrograde evaluation of urethra done. Patient underwent cystoscopy and was found to 3 cases have PUV just distal to verumontanum in patients and one case is proximal to verumontanum .All Patient underwent ablation of posterior urethral valve using Collin's knife .14 fr silastic catheter placed for all cases , catheter removed postoperative day 5, postoperative uroflow done for all cases,

shows improvement in uroflow parameter, patients were follow up for 6 months , 2 patients were underwent renal transplant in follow up periods.

MCU



*\*Corresponding author: Aysha Shaheen,*  
Department of Urology, Government Kilpauk Medical College, Chennai

## DISCUSSION

Late presentation of PUV is a rare condition and it has been estimated that it accounts for 10% of PUV cases.<sup>10</sup> The usual presentation is prenatal or at birth. Poor or weak stream, dribbling voiding, repeated urinary tract infection and chronic renal failure are the most common clinical pictures in adolescents and adults.<sup>11</sup> In most cases, PUV fulguration improves the signs and symptoms of obstructive infravesical syndrome while preserving renal function and renal morphology.<sup>12</sup>

Many common conditions are superimposed on late PUV, such as benign prostate hypertrophy, urethral stenosis, prostatitis, urethritis and sphincter-bladder dyssynergy.

However, late presentation of PUV could be a cause of chronic renal failure whether or not it has been treated. Parkhouse *et al.*<sup>13</sup> reported on long-term follow-up among treated post pubertal patients and showed that 26% of them had had chronic or end-stage renal failure.<sup>13</sup> very few cases are PUV cases have been described in the literature. This number is smaller than might have been reported, because of diagnostic difficulties and the existence of other, similar diseases. As urologists must remain alert to the possibility of late diagnoses of PUV, especially among adults.

## CONCLUSION

Since PUV is a rare condition in adults and the diagnosis of PUVs is also difficult in these groups we must consider this situation during evaluation of adult patients with obstructive symptoms especially during cystourethroscopy.

## Reference

1. Atwell JD. Posterior urethral valves in the British Isles: A multicentre BAPS review. *J Pediatr Surg.* 1983;18 (1):70–74. doi: 10.1016/S0022-3468(83)80276-0.
2. Opsomer RJ, Wese FX, Dardenne AN, Van Cangh PJ. Posterior urethral valves in adults males. *Urology.* 1990; 36 (1):35–37. doi: 10.1016/0090-4295(90)80309-B.

3. Dinneen MD, Duffy PG. Posterior urethral valves. *Br J Urol.* 1996;78 (2):275–281.
4. Hendren WH. Posterior urethral valves in boys: a broad clinical spectrum. *J Urol.* 1971;106 (2):298–302.
5. Denes ED, Barthold JS, Gonzalez R. Early prognostic value of serum creatinine levels in children with posterior urethral valves. *J Urol.* 1997;157(4):1441–1443. doi: 10.1016/S0022-5347(01)65015-8.
6. Mahony T, Laferte RO. Congenital posterior urethral valves in adult males. *Urology.* 1974;3(6):724–734. doi: 10.1016/S0090-4295(74)80214-1.
7. Saraf PG, Valvo JR, Frank IN. Congenital posterior urethral valves in an adult. *Urology.* 1984;23 (1):55–57. doi: 10.1016/0090-4295(84)90177-8.
8. Páramo PG, Martínez-Piñeiro JA, De La Peña JJ, Páramo PS., Jr Andrological implications of congenital posterior urethral valves in adults: a case of retained ejaculation and review in Western literature. *Eur Urol.* 1983;9 (6):359–361.
9. Köksal IT, Usta M, Erdogru T, Ates, M, Kukul E, Baykara M. Incidental adult posterior urethral valve without clinical features. *Int Urol Nephrol.* 2003;35 (2):227–229.
10. Young HH, Frontz WA, Baldwin JC. Congenital obstruction of the posterior urethra. *J Urol.* 1919;3:289-365. *J Urol.* 2002;167 (1):265-7; discussion 268.
11. Bomalaski MD, Anema JG, Coplen DE, Koo HP, Rozanski T, Bloom DA. Delayed presentation of posterior urethral valves: a not so benign condition. *J Urol.* 1999;162 (6):2130-32.
12. Martin J, Anderson J, Raz S. Posterior urethral valves in adults: a report of 2 cases. *J Urol.* 1977;118 (6):978-9.
13. Parkhouse HF, Barratt TM, Dillon MJ, *et al.* Long-term outcome of boys with posterior urethral valves. *Br J Urol.* 1988;62 (1):59-62.

### How to cite this article:

Aysha Shaheen (2019) Adult Posterior Urethral Valve: A Case Series', *International Journal of Current Advanced Research*, 08(12), pp. 20790-20791. DOI: <http://dx.doi.org/10.24327/ijcar.2019.20790.4069>

\*\*\*\*\*