

STRANGULATED SMALL BOWEL HERNIATION THROUGH IATROGENIC UTERINE PERFORATION-A RARE CASE REPORT

Jainendra K. Arora, Ravikiran B, Snigdha K, Sunil K.Jain, Praveen V, Jaspreet S. Bajwa*, Sanjana K and Manjunath S

Department of General Surgery, Safdarjung Hospital, New Delhi

ARTICLE INFO

Article History:

Received 6th August, 2019

Received in revised form 15th September, 2019

Accepted 12th September, 2019

Published online 28th November, 2019

ABSTRACT

Bowel herniation through a perforated uterus is a very rare condition .Till now 10 cases of intrauterine bowel herniation have been reported. Here we report a rare case of a strangulated small bowel hernia through an iatrogenic uterine perforation in the first trimester that presented as acute intestinal obstruction.

Key words:

Strangulated small bowel, uterine perforation

Copyright©2019 Jainendra K. Arora et al. This is an open access article distributed under the Creative Commons Attribution License, which permits unrestricted use, distribution, and reproduction in any medium, provided the original work is properly cited.

INTRODUCTION

Abortions, especially if done by inexperienced hands can lead to serious complications such as uterine perforation. Uterine perforation may not be recognized at the time of the procedure, and patients may present days or weeks later with sequelae of the complication. We are describing a rare case of a woman presenting 2days after an abortion, with small bowel herniation into a perforated uterus causing obstruction. Clinical examination and ultrasound correlation were highly suggestive of this diagnosis preoperatively. We discuss the diagnosis and management of this rare finding.

Case report

A 20 year old nulliparous married female presented to the emergency with chief complaints of abdominal pain and distension for the past 2 days and non passage of stools , flatus and multiple episodes of bilious vomiting for 1day. She had a history of dilatation and curettage 3 days back, following a period of amenorrhea of 1.5 months. She also had history of fever episodes.

On examination, patient was pale with tachycardia and hypotension. Per abdomen examination revealed distended abdomen with diffuse tenderness, guarding and absent bowel sounds. Emergency hematological investigations revealed anemia (Hb-8gms/dl), leucocytosis (tlc23900cells/cumm).Per vaginal examination revealed bowel loops protruding through the os.

Sonography revealed a rent in the uterus with omentum protruding through the utero-cervical canal with grossly dilated bowel loops (Fig.1) Patient was optimised and taken up for emergency laparotomy in view of uterine perforation and acute intestinal obstruction.

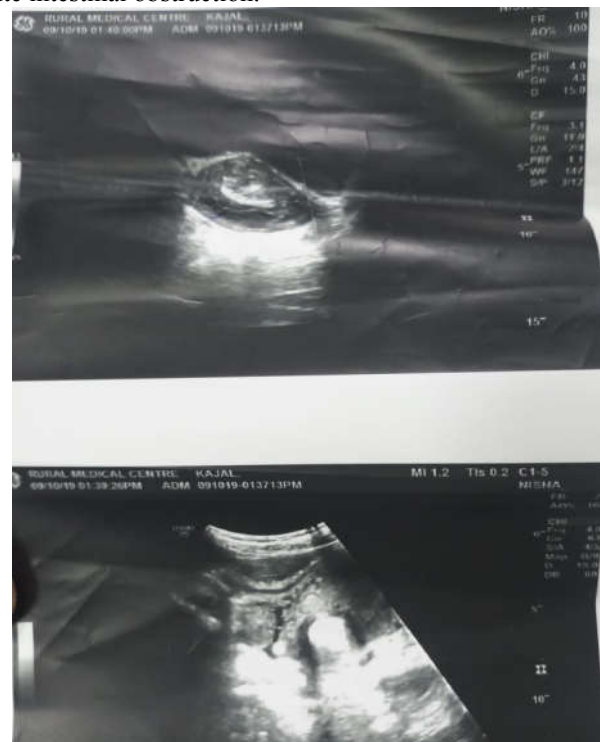

Fig 1 Ultrasonograph Revealing A Breach In Serosal Surface Of Uterine Wall With Omentum And Bowel Protruding Into The Uterocervical Canal

*Corresponding author: **Jaspreet S. Bajwa**

Department of General Surgery, Safdarjung Hospital, New Delhi

Intra operatively, a 4×2 cm perforation present over posterior wall of uterus with 10 cm of ileal segment 0.5 feet proximal to ICJ found herniating through it(Fig.2).Herniated ileal segment was gangrenous(Fig.3). Rest of the bowel and solid organs were normal with no free fluid in the abdomen. 10 cm of the gangrenous ileal segment was resected and a double barrel ileostomy was made ½ feet proximal to the ICJ. The uterine perforation was repaired in two layers(Fig.4). Post operatively, recovery was uneventful and the patient was discharged to be planned for bowel continuity restoration surgery at a later date.

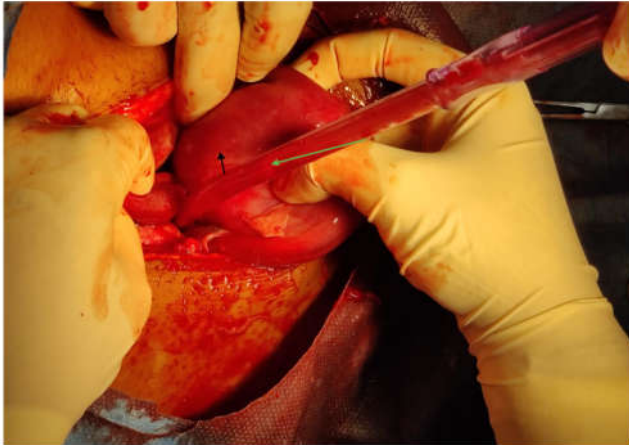


Fig 2 Intraoperative Photo Showing Rent In Uterus With Small Bowel Herniating Through IT.

Long Arrow: Representing Perforation in Posterior Wall of Uterus
Short Arrow: Representing Bowel Loops Entering Into the Uterine Perforation

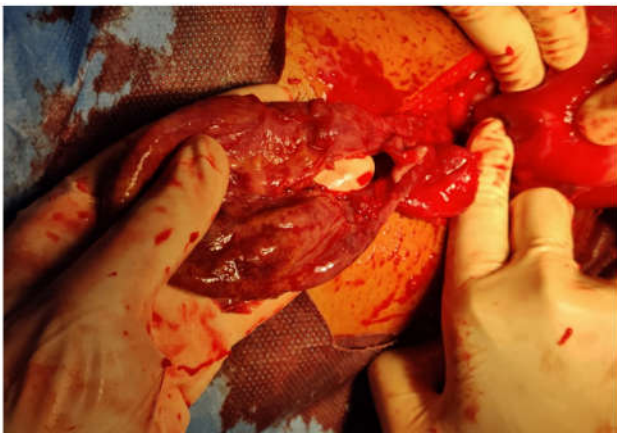

Fig 3 Showing Gangrenous Changes in The Herniated Bowel Loop After Reduction

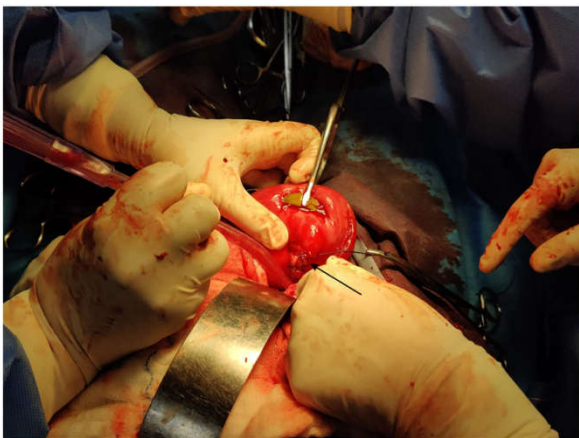


Fig 4 Showing Uterus after Primary Repair of Perforation

DISCUSSION

Elective abortion is relatively a safe procedure but serious complications may occur which includes infection, hemorrhage, atony, and uterine perforation(1).Serious consequences may result, such as intestinal trauma, which may require bowel resection, uncontrolled bleeding may sometimes necessitate a hysterectomy and infections or even death(2).Second trimester abortion has a higher rate of complications than abortions performed in the first trimester. Despite this, most reports of intrauterine bowel have occurred after first trimester abortions. Uterine perforation during abortion has reported at a rate of 0.05-1.9%(3).

Several risk factors for uterine perforation during abortion have been identified out of which strongest predictor is surgeon experience. Other risk factors include advanced maternal age, multiparity, retroverted uterus, history of prior abortion or cesarean section, history of previous uterine perforation(4) Uterine perforations including those containing prolapsed bowel, usually present days to weeks after the procedure. Usually presents with features of obstruction but some patients may also present with nonspecific symptoms including pain, fever, chills, vomiting, and diarrhoea, which can lead to a delay in surgical therapy. The differential diagnosis of a post-abortion perforated uterus includes retained products of conception, pelvic inflammatory disease, and various non-gynecological causes of abdominal pain. Hence, radiological evaluation is necessary and can be of significant aid in diagnosing these patients. Dunner et al. first reported such a case in 1983(5) utilizing ultrasound. Ultrasound showing tubular material in the endometrial cavity with the presence of air is suggestive of bowel. The first reported CT diagnosis of incarcerated bowel in a uterine perforation was by Dignac et al. in 2008(6).

Evaluation with CT has an important diagnostic role in cases where ultrasound is ambiguous or if non- gynecological pathology is suspected. Although the uterine wall can hinder visualization of intrauterine bowel loops, Dignac et al. emphasize that the bowel's mesentery can be well visualized on CT scan due to its fatty nature, and should be a red flag for intrauterine bowel.

Our patient's history, clinical examination and radiological evidence strongly suggested the diagnosis preoperatively. Ultrasound showed a linear defect in the posterioruterinewall with echogenic content suggestive of omentum protruding through it..

Although some cases of uterine perforation can be managed conservatively(7),the diagnosis of intrauterine bowel mandates laparotomy. this possibility should be strongly suspected as the intrauterine location of strangulated bowel may mask the characteristic peritoneal signs. The ileum and sigmoid are the most commonly injured segments of bowel when the uterus is perforated(8-10), and in one reported case, the appendix became incarcerated in the uterine perforation. The bowel should be reduced into the abdomen and evaluated, and the uterine laceration should be repaired. Rarely, a hysterectomy is required if the uterus is necrotic or irreparable. The involved herniated bowel may be strangulated, have direct bowel wall trauma, or may be devascularized by injury or incarceration of

the mesentery. Depending on the extent of injury, significant portions of bowel may require resection with or without diversion(11).

CONCLUSIONS

Abortions are an important medico- social issue. Pregnancy terminations may have serious and potentially fatal complications. Uterine perforation during abortion is usually asymptomatic and generally can be managed conservatively, but herniation of bowel through the uterine defect can result in obstruction and strangulation. Intrauterine bowel requires prompt laparotomy and possible resection of non-viable bowel. Although ultrasound and CT scan may aid in the diagnosis of this rare complication, a high clinical suspicion for uterine perforation should be maintained by health care providers when treating patients who have had an abortion.

References

1. Jain V, Saha SC, Bagga R, Gopalan S. Unsafe abortion: a neglected tragedy. Review from a tertiary care hospital in India. *Journal of Obstetrics and Gynaecology Research*. 2004 Jun;30(3):197-201.
2. Oludiran OO, Okonofua FE. Morbidity and mortality from bowel injury secondary to induced abortion.
3. Bhattacharya S, Mukherjee G, Mistri P, Pati S. Safe abortion—Still a neglected scenario: a study of septic abortions in a tertiary hospital of Rural India. *Online Journal of Health and Allied Sciences*. 2010 Jul 30;9(2)
4. Guerra F, Bencini L. Unsafe abortion. *European Journal of Obstetrics and Gynecology and Reproductive Biology*. 2016 Mar 1; 198:162-3.
5. Dunner PS, Thomas MA, Ferreras M, Jerome M. Intrauterine incarcerated bowel following uterine perforation during an abortion: a case report. *American journal of obstetrics and gynecology*. 1983 Dec 15;147(8):969.
6. Dignac A, Novellas S, Fournol M, Caramella T, Bafghi A, Chevallier P. Incarceration of the appendix complicating a uterine perforation following surgical abortion: CT aspects. *Emergency radiology*. 2008 Jul 1;15(4):267-9.
7. Kaali SG, Szigetvari IA, Bartfai GS. The frequency and management of uterine perforations during first-trimester abortions. *American journal of obstetrics and gynecology*. 1989 Aug 1;161(2):406-8.
8. Coffman S. Bowel injury as a complication of induced abortion: a case report and literature review. *The American surgeon*. 2001 Oct 1; 67(10):924.
9. Ntia IO, Ekele BA. Bowel prolapse through perforated uterus following induced abortion. *West African journal of medicine*. 2000;19(3):209-11.
10. Jhobta RS, Attri AK, Jhobta A. Bowel injury following induced abortion. *Int J Gynaecol Obstet* 2007;96:24–7.
11. Coughlin LM, Sparks DA, Chase DM, Smith J. Incarcerated small bowel associated with elective abortion uterine perforation. *The Journal of emergency medicine*. 2013 Mar 1;44(3):e303-6.

How to cite this article:

Jainendra K. Arora *et al* (2019) 'Strangulated Small Bowel Herniation through Iatrogenic Uterine Perforation-A Rare Case Report', *International Journal of Current Advanced Research*, 08(11), pp. 20458-20460.
DOI: <http://dx.doi.org/10.24327/ijcar.2019.20460.3998>
