



ISSN: 2319-6505

Available Online at <http://journalijcar.org>

*International Journal of Current Advanced Research*  
Vol 5, Issue 5, pp 871-873, May 2016

*International Journal*  
*of Current Advanced*  
*Research*

ISSN: 2319 - 6475

RESEARCH ARTICLE

**EARLY STAGE OF HOOKWORM INFECTION WITH MILD ANAEMIA AND ITS RELATION WITH STOOL EXAMINATION FOR HOOKWORM OVA IN PATIENTS WITH HOOKWORM INFECTION FOUND WHILE DOING ENDOSCOPY**

**Govindarajalu Ganesan\***

Department of General surgery Indira Gandhi Medical College and Research Institute, Puducherry-605009

**ARTICLE INFO**

**Article History:**

Received 16<sup>th</sup> February, 2016  
Received in revised form 27<sup>th</sup> March, 2016  
Accepted 15<sup>th</sup> April, 2016  
Published online 28<sup>th</sup> May, 2016

**Key words:**

Mild anaemia, Early Stage of Hookworm Infection, Stool Examination for Hookworm ova, Upper Gastro Intestinal Endoscopy

**ABSTRACT**

**Objective** A detailed study was done to know about the occurrence of mild anaemia and its relation with stool examination for hookworm ova in patients with early stage of hookworm infection found while doing upper gastro intestinal endoscopy

**Methods** A study of 1259 patients who had undergone upper gastro-intestinal endoscopy for a period of 5 years from May 2009 to April 2014 was carried out. In all the patients found to have hookworms in duodenum, investigations were done to know about the occurrence of various grades of anaemia. In all the patients with severe anaemia, stool examination was done for hookworm ova. But in one patient with mild anaemia [haemoglobin 10 to 12 g/dl or g%], stool examination was also done for hookworm ova to know about the occurrence of mild anaemia and its relation with stool examination for hookworm ova in patients with early stage of hookworm infection. In the other patients with mild anaemia stool examination could not be done. The results were found as given below.

**Results** Out of these 1259 patients, 14 patients found to have hookworms in duodenum while doing upper gastro-intestinal endoscopy were taken into consideration for our study. Out of these 14 patients, 2 patients had severe anaemia and 6 patients had mild anaemia. In all the patients with severe anaemia, stool examination was negative for hookworm ova. But stool was also hookworm ova in one patient with mild anaemia [haemoglobin 10 to 12 g/dl or g%]. In the other patients with mild anaemia stool examination could not be done.

**Conclusion** Thus upper gastro intestinal endoscopy should be done to confirm the presence of hookworms even when there is mild anaemia in tropical countries since stool examination can be negative for hookworm ova in this early stage of hookworm infection with mild anaemia.

© Copy Right, Research Alert, 2016, Academic Journals. All rights reserved.

**INTRODUCTION**

Many studies have shown the presence of anaemia in hookworm infection [1 to 18]. But so far detailed study was not done to know about the occurrence of mild anaemia and its relation with stool examination for hookworm ova in patients with early stage of hookworm infection. Hence a detailed study was done to know about the occurrence of mild anaemia and its relation with stool examination for hookworm ova in patients with early stage of hookworm infection found while doing upper gastro intestinal endoscopy.

**MATERIALS AND METHODS**

This study was conducted in the department of general surgery, Aarupadai Veedu Medical College and Hospital, Puducherry. A study of 1259 patients who had undergone upper gastro-intestinal endoscopy for a period of 5 years from May 2009 to April 2014 was carried out in Aarupadai Veedu Medical College and Hospital, Puducherry. In each of these

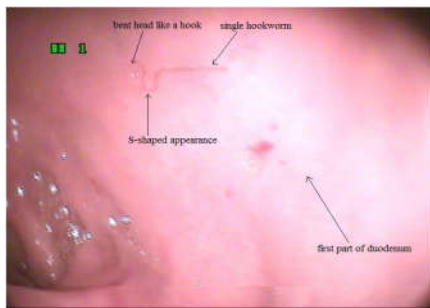
1259 patients, the first and second parts of duodenum were carefully examined to find out the presence of single or multiple hookworms. In all the patients found to have hookworms in duodenum, investigations were done to know about the presence of anaemia. Anaemia is defined as haemoglobin <12 g/dl or 12 g% in women and haemoglobin or <13 g/dl or 13 g% in men. Mild anaemia is taken as haemoglobin 10 to 12 g/dl or g%, moderate anaemia is taken as haemoglobin 7 to 10 g/dl or g% and severe anaemia is taken as haemoglobin <7 g/dl or g%. In all the patient with severe anaemia, stool examination was done for hookworm ova. But in one patient with mild anaemia [haemoglobin 10 to 12 g/dl or g%], stool examination was also done for hookworm ova to know about the occurrence of mild anaemia and its relation with stool examination for hookworm ova in patients with early stage of severe hookworm infection. In the other patients with mild anaemia stool examination could not be done. The results were found as given below.

## RESULTS

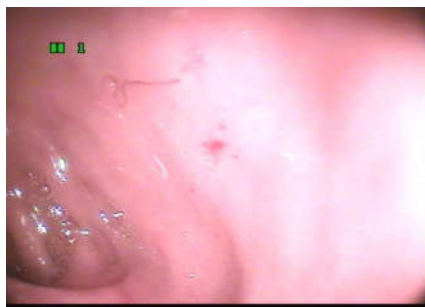Out of these 1259 patients, 14 patients found to have hookworms in duodenum while doing upper gastro-intestinal endoscopy were taken into consideration for our study. Out of these 14 patients, 9 patients' had anaemia. Out of these 9 patients with anaemia, 2 patients were found to have severe anaemia and 6 patients had mild anaemia. In all the patients with severe anaemia, stool examination was negative for hookworm ova. But stool examination was also negative for hookworm ova in one patient with mild anaemia.

### Mild Anaemia with negative stool Examination for Hookworm Ova

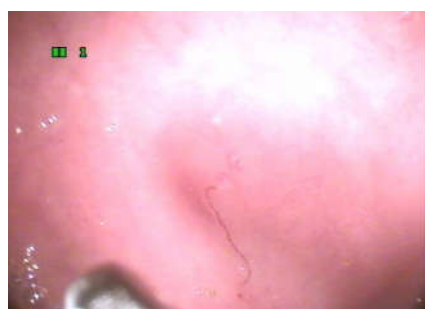- Of the 9 patients with anaemia, 6 patients were found to have mild anaemia.
- But stool examination was negative for hookworm ova in one patient with mild anaemia [haemoglobin in 10g/dl or g%]. In the other patients with mild anaemia, stool examination could not be done.



**Figure 1** Single hookworm in duodenum with its bent head like a hook and S-shaped appearance in the patient with mild anaemia [Haemoglobin 10 g%] with negative stool examination For Hookworm ova



**Figure 2** single hookworms in duodenum with its bent head like a Hook and S-shaped appearance in the same patient with Mild Anaemia [haemoglobin 10g/dl or g%] with Negative Stool Examination for hookworm Ova [different view].



**Figure 3** single hookworms in duodenum with its bent head like a hook and S-shaped appearance in the same patient with mild Anaemia [haemoglobin 10g/dl or g%] with negative stool examination for hookworm ova [different view].

- The single hookworm in duodenum found in the patient with mild anaemia [haemoglobin 10 g%] with negative stool examination for hookworm ova is shown in Fig 1, 2, 3.
- The hookworm in duodenum is identified by its bent head which looks like a hook (Fig1, 2, 3) and by its S-shaped appearance (13) (Fig1, 2, 3).

## DISCUSSION

Hookworms are estimated to infect more than 740 million people around the world, but most people who are infected are asymptomatic [13]. Hookworm usually lives in the upper part of small bowel. Iron deficiency anemia secondary to loss of iron into the gut is the most significant risk of hookworm infection [13]. The prevalence of infection is as high as 80% in tropical areas within developing countries [13]. Definite diagnosis is made by seeing hookworm eggs during stool examination, however sometimes its diagnosis can be missed [13]. The low diagnostic yield can be attributed to several causes [19]. Many patients are evaluated relatively early after symptom onset, whereas the time to patency (the appearance of ova in stool) for some helminths is measured in months [19]. The yield of routine stool examination for ova is known to be inadequate because of a low burden of infection in patients, even when serial samples are evaluated [19]. Sensitive serologic tests for many pathogens are not available at all, whereas to some, the tests are not commercially available [19].

Hookworms accounted for one third of all helminthic infections in one study [19]. Among them, a clinical diagnosis of human hookworm infection was made in three cases, based on a typical papular, intensely pruritic non-creeping eruption and dry cough [19]. However, these symptoms appear in the pre-patent period, where the chance to detect ova is nil, and a serologic test is not available for this parasite [19]. This lack of a serologic test probably contributes to the overall poor diagnostic yield [19]. Hence upper gastro intestinal endoscopy should be done to confirm the presence of hookworms even when there is mild anaemia in tropical countries since stool examination is usually negative for hookworm ova in this early stage of hookworm infection.

### Stool Examination Likely to be Negative for Hookworm Ova in the Early Stage of Hookworm Infection

- Hookworm infection is sometimes not easy to be detected in stools [13].
- Stool examination for hookworm ova should not be considered as a sensitive test to identify early stage of hookworm infection since egg laying may be delayed [13].
- The yield of routine stool examination for hookworm ova is known to be inadequate because of low burden of infection, even when serial samples are evaluated [19].
- Hence stool examination is also likely to be negative for hookworm ova due to very low burden of hookworms in the early stage of hookworm infection.
- Stool examination is likely to be negative for hookworm ova if the stool samples are evaluated relatively early after the onset of symptoms because the time to

- Patency [the appearance of ova in stools] for some helminths like hookworms is measured in months which is about one and half months [5 to 6 weeks] for hookworms [19].
- Hence stool examination is also usually negative for hookworm ova in the early stage of hookworm infection since the time to patency [the appearance of ova in stools] is 5 to 6 weeks for hookworms [19].

## CONCLUSION

- Hence, in the early stage of hookworm infection stool examination is likely to be negative for hookworm ova.
- Stool examination is likely to be negative for hookworm ova due to very low burden of hookworms in the early stage of hookworm infection.
- Stool examination is also usually negative for hookworm ova in the early stage of hookworm infection since egg laying may be delayed and the time to patency [the appearance of ova in stools] is 5 to 6 weeks for hookworms.
- Since anaemia is mild and stool examination is usually negative for hookworm ova in this early stage of hookworm infection, upper gastro intestinal endoscopy is the only possible investigation to confirm the presence of hookworms in this stage.
- Hence upper gastro intestinal endoscopy should be done to confirm the presence of hookworms even when there is mild anaemia in tropical countries since stool examination is usually negative for hookworm ova in this early stage of hookworm infection.

## Acknowledgement

The author sincerely thanks the staff nurse Nithya who was assisting the author while doing endoscopy and the staff nurses A.K. Selvi and Nithya for their immense help rendered to the author while conducting this work. The author acknowledges the immense help received from the scholars whose articles are cited and included in references of this manuscript. The author is also grateful to authors / editors / publishers of all those articles, journals and books from where the literature for this article has been reviewed and discussed.

## References

1. Hyun HJ, Kim EM, Park SY, Jung JO, Chai JY, Hong ST. A case of severe anemia by *Necator americanus* infection in Korea. *J Korean Med Sci.* 2010 Dec; 25(12):1802-4.
2. Wu KL, Chuah SK, Hsu CC, Chiu KW, Chiu YC, Changchien CS. Endoscopic Diagnosis of Hookworm Disease of the Duodenum: A Case Report. *J Intern Med Taiwan* 2002; 13:27-30.
3. Kuo YC, Chang CW, Chen CJ, Wang TE, Chang WH, Shih SC. Endoscopic Diagnosis of Hookworm Infection That Caused Anemia in an Elderly Person. *International Journal of Gerontology.* 2010 ; 4 (4) : 199-201
4. Zaher, T. I, Emara, M. H., Darweish, E., Abdul-Fattah, M., Bihery, A. S., Refaey, M. M & Radwan, M.I. Detection of Parasites during Upper Gastrointestinal Endoscopic Procedures.

- Afro-Egypt *J Infect Endem Dis* 2012; 2 (2): 62-68.
5. Basset D, Rullier P, Segalas F, Sasso M. Hookworm discovered in a patient presenting with severe iron-deficiency anemia *Med Trop (Mars).* 2010 Apr; 70(2):203-4
6. Lee T.-H, Yang J.-c, L in J.-T, LuS.-C and Wang T.-H. Hookworm Infection Diagnosed by Upper Gastrointestinal Endoscopy: —Report of Two Cases with Review of the Literature—. *Digestive Endoscopy*, 1994 6(1): 66–72
7. Kato T, Kamoi R, Iida M, Kihara T. Endoscopic diagnosis of hookworm disease of the duodenum *J Clin Gastroenterol.* 1997 Mar;24(2):100-102
8. Anjum Saeed, Huma Arshad Cheema, Arshad Alvi, Hassan Suleman. Hookworm infestation in children presenting with malena -case series *Pak J Med Res Oct - Dec 2008;47(4) :98-100*
9. Li ZS1, Liao Z, Ye P, Wu RP Dancing hookworm in the small bowel detected by capsule endoscopy: a synthesized video. *Endoscopy.* 2007 Feb; 39Suppl 1: E97. Epub 2007 Apr 18.
10. Kalli T1, Karamanolis G, Triantafyllou K Hookworm infection detected by capsule endoscopy in a young man with iron deficiency. *Clin Gastroenterol Hepatol.* 2011 Apr; 9(4):e33
11. Chen JM1, Zhang XM, Wang LJ, Chen Y, Du Q, Cai JT. Overt gastrointestinal bleeding because of hookworm infection. *Asian Pac J Trop Med.* 2012 Apr; 5(4):331-2.
12. A Rodríguez, E Pozo, R Fernández, J Amo, T Nozal. Hookworm disease as a cause of iron deficiency anemia in the prison population *Rev Esp Sanid Penit* 2013; 15: 63-65
13. Cedrón-Cheng H, Ortiz C (2011) Hookworm Infestation Diagnosed by Capsule Endoscopy. *J Gastroint Dig Syst* S1:003. doi: 10.4172/2161-069X.S1-003
14. Yan SL, Chu YC. Hookworm infestation of the small intestine *Endoscopy* 2007; 39: E162±163
15. Chao CC1, Ray ML. Education and imaging. Gastrointestinal: Hookworm diagnosed by capsule endoscopy. *J Gastroenterol Hepatol.* 2006 Nov; 21 (11):1754.
16. Christodoulou, D. K., Sigounas, D. E., Katsanos, K. H., Dimos, G & Tsianos, E. V.. Small bowel parasitosis as cause of obscure gastrointestinal bleeding diagnosed by capsule endoscopy. *World journal of gastrointestinal endoscopy*, 2(11), 2010: 369.
17. Genta RM, Woods KL. Endoscopic diagnosis of hookworm infection. *Gastrointest Endosc* 1991 July; 37(4):476-8
18. Nakagawa Y, Nagai T, Okawara H, Nakashima H, Tasaki T, Soma W, *et al.* Comparison of magnified endoscopic images of *Ancylostomaduodenale* (hookworm) and *Anisakis simplex*. *Endoscopy* 2009; 41 (Suppl. 2): E189
19. Meltzer E, Percik R, Shatzkes J, Sidi Y, Schwartz E. Eosinophilia among returning travelers: a practical approach *Am J Trop Med Hyg.* 2008 May; 78(5):702-9.